

**G, E, Male AGE 75**

The patient presented to us with a history of metastatic colon cancer, bladder cancer and probable lung cancer, (patient refused biopsy to determine if mass was malignant). The patient was very frail, weak, and severely depressed. He has severe back pain from osteoarthritic changes in his back and he is walking with a walker. His depression is worsened by the fact he has a terminally ill wife in hospice care.

Following the start of the LifeOne Formula the patient has become much more energetic and has had the strength to go through some personal issues concerning his terminally ill wife. He no longer uses the walker and is generally good health, with a much more optimistic disposition.

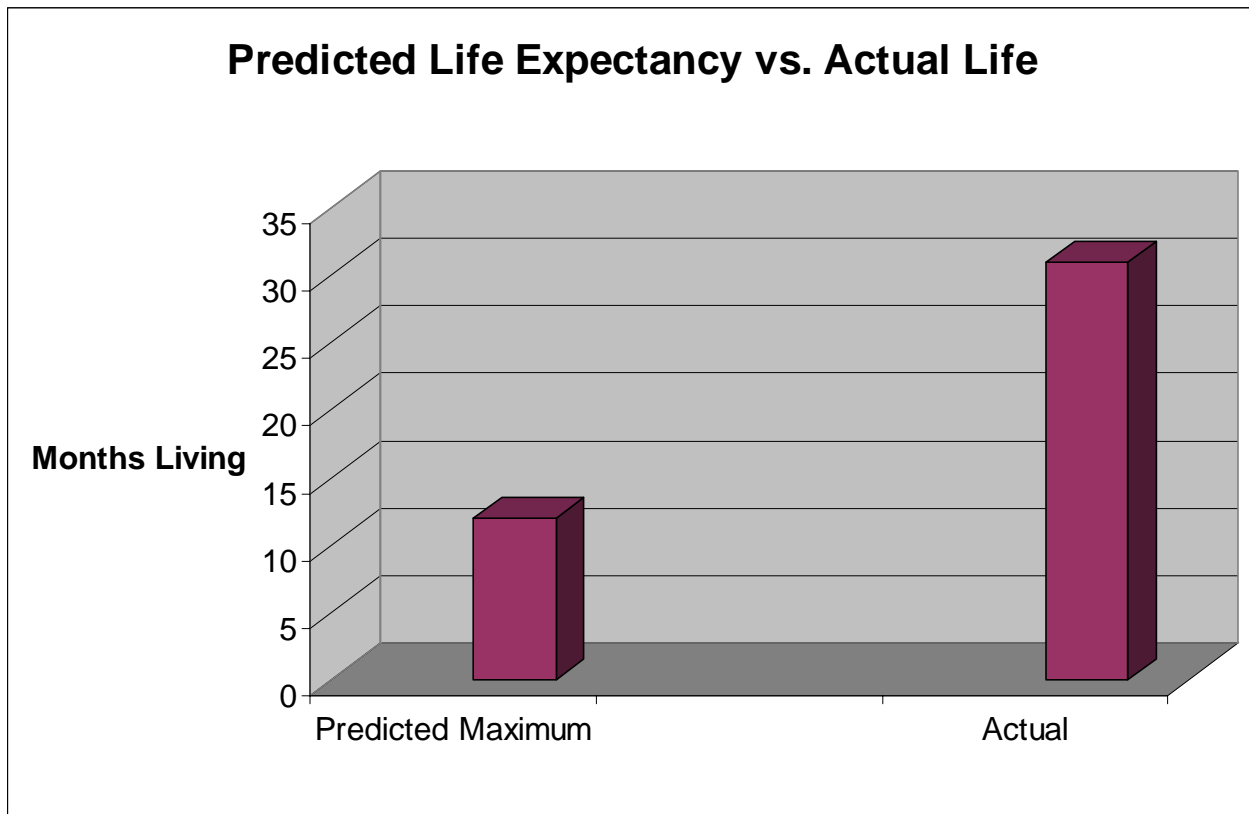
09/09/99 Colon Cancer Determined by biopsy and bladder cancer determined by biopsy

02/04/02 X-ray shows mass in left lung believed to be cancer. Due to health and position of tumor, a biopsy has not been ordered.

03/11/02 Started LifeOne Formula

04/17/02 Bladder Tissue biopsy shows no cancer and minimal inflammation, no other signs of disease. Colon cancer is no longer detectable, confirmed through colonoscopy and biopsy.

5/10/02 AMAS shows borderline result. We will recheck in 60-90 days.



\*The patient is still living and doing well at the time of this report.

Median survival reference is a direct comparison to Chemo Therapy with similar patients.

Cancer Biother Radiopharm 2000 Apr;15(2):175-83

Chemo-biotherapy with 5-fluorouracil, leucovorin, and alpha interferon in metastatic carcinoma of the colon--a Cancer Biotherapy Research Group [CBRG] phase II study.

Soori GS, Oldham RK, Dobbs TW, Bury MJ, Church CK, DePriest C.

Alegent Health Bergan Mercy Cancer Center, Omaha, NE 68124, USA.